

## skinthings

Dr Adrian Lim

coordinated by Dr Stephen Shumack

# The plethoric face

A 55-year-old man with rosacea presents with facial erythema and telangiectasias. He is perturbed by the flushed appearance and the perception that he drinks too much. How can this man be helped?

## The problem

Facial telangiectasias (FT) are commonly idiopathic where small red or purple vessels are present on the cheeks, around the nose (alar groove) and the chin. These vessels are post-capillary venules rather than true capillaries and are usually less than 1 mm in diameter. Apart from being a cosmetic concern, the vessels often worsen skin flushing and burning. FT are usually chronic and progressive, becoming more prominent with time and ongoing sun exposure.

## Causes and associations

FT is a well-known feature of rosacea, and can be aggravated by heat, ultraviolet light, alcohol, spicy food, anxiety/emotional stress and vasodilator medications. FT is also associated with sun damage.

## Physical therapy options

- Laser (e.g. 595 nm pulsed dye laser)
- Intense pulsed light (IPL)
- Hyfrecaction
- Sclerotherapy.

Lasers are traditionally most effective for FT. Pulse dye lasers (595 nm wavelength) are very effective but may produce purpura, lasting 7-14 days. Sub-purpuric settings can be used but may not be as effective, requiring additional treatments. Other laser wavelengths such as 532 nm and 1064 nm can also

be effective.

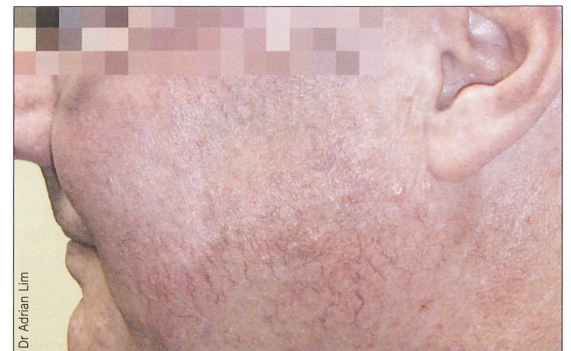IPL can also be used for FT. It is purpura free and has a larger treatment head that enables faster treatments. Multiple treatments may be required. Both IPL and laser are less painful when used in conjunction with a skin-cooling device.

Hyfrecaction (or electrocautery) is effective when the laser/IPL option is not available.

Sclerotherapy is effective for coarser FT but unsuitable for smaller vessels and diffuse erythema.

## Management

The underlying rosacea needs to be well managed. Tetracyclines are helpful for the inflammatory papules and pustules. The patient should avoid the factors that may



Dr Adrian Lim


aggravate the condition.

This patient was treated with a new generation IPL (Sciton BBL). The patient experienced a mild degree of facial oedema and erythema post treatment. These changes usually last for a couple of days, and have the appearance of moderate sunburn.

For the 48 hours post treatment, the patient should avoid any activities that may lead to flushing, such as sun exposure, excess heat and alcohol. Uncommonly, complications of IPL/laser include blisters, burns, pigmentary alterations (especially with darker or recently tanned skin), and rare

cases of scarring.

IPL may also worsen some photosensitive conditions such as lupus.

The patient was pleased with the improvement from the first treatment. For best results, patients may require up to three treatments. It is important to warn patients that it is natural for the telangiectasias to recur over years but this can be addressed with repeat treatments. 

*The author, Dr Adrian Lim, is a fellow of the Australasian College of Dermatologists. Dr Stephen Shumack is the Honorary Secretary of the Australasian College of Dermatologists.*